

CASE REPORT: AN INCOMPLETE MOLAR PREGNANCY WITH UNUSUAL COMPLICATIONS

Namus Muhajir Nur, MD¹, Mahlet Yigeremu Gebremariam, MD¹

ABSTRACT

INTRODUCTION:

Gestational trophoblastic diseases (GTD) are a heterogeneous group of gestational and neoplastic conditions arising from the trophoblast. It is uncommon for gestational trophoblastic disease to present with Preeclampsia and syndrome prior to 24 weeks gestation.

CASE PRESENTATION

We present an unusual case of partial molar pregnancy which was diagnosed with severe preeclampsia and Partial HELLP associated with Severe anemia, Sepsis, Hyperthyroidism, Thrombocytopenia & CHF at 03 months of amenorrhea with ultrasound and Histopathology confirmed an incomplete molar pregnancy.

Evacuation of the Uterus resulted in rapid resolution of signs, symptoms, and laboratory abnormalities.

CONCLUSION

This case demonstrates the acuteness in which life-threatening maternal conditions can arise with this uncommon complication of pregnancy, and the importance of early & correct identification of the characteristic laboratory & ultrasonographic findings associated with a molar pregnancy.

KEY WORDS: Molar pregnancy, Preeclampsia, HELLP syndrome

(Ethiopian Journal of Reproductive Health; 2019; 11;1:71-77)

1 Department of Obstetrics and Gynecology, College of Health Sciences, Addis Ababa University, Addis Ababa, Ethiopia

INTRODUCTION

Usually patients with partial hydatidiform mole will not have the dramatic clinical features characteristic of complete molar pregnancy and is uncommon to present with with Preeclampsia and syndrome. We present here an unusual case of partial molar pregnancy which was diagnosed with severe preeclampsia and Partial HELLP associated with Severe anemia, Sepsis, Hyperthyroidism, Thrombocytopenia & CHF at 03 months of amenorrhea. Histopathology confirmed an incomplete molar pregnancy. The case summary followed by a brief discussion of the case is presented.

CASE SUMMARY

A 20-year-old primigravida lady from Addis Ababa, Ethiopia presented with vaginal bleeding of one-week duration following 03 months of amenorrhea. The bleeding was stated to be profuse during the initial 03 days then becomes intermittent and spotting. She also gave history of a progressively increasing abdominal distention especially over later three weeks prior to presentation. She had also nausea & Vomiting for about 2months prior to presentation with associated diarrhea of 2weeks duration. She noted intermittent fever, Palpitation, dizziness & easy fatigability which was associated with Cough, shortness of breath, orthopnea of 02 pillows & paroxysmal nocturnal dyspnea for

10days. She had no antenatal care in the index pregnancy. Her previous medical and obstetrical history was unremarkable. The pregnancy was uneventful until her presentation.

On examination she was in cardiorespiratory distress and looked very pale. Her Pulse rate ranged between 130 and 136 bpm, Respiratory rate ranged between 26 and 28, Blood pressure was ranging 140/70 -140/100 mg, and Body temperature was ranging between 37.2-37.5oC. There was a 3x4cm non-tender and firm anterior neck mass which moves with deglutition. On the chest examination dullness to percussion and decreased air entry bilaterally and basally noted. The pericardium was active with S3 gallop and ejection systolic murmur. The abdominal examination revealed a uterine size of 20 weeks of pregnancy with no clear palpable fetal parts, with tender hepatomegaly. The vulva was blood soaked with the Cervix admitting one finger, 50%effaced, posterior & soft, and friable tissue was palpable above the cervical Os. There was a Grade -II pedal & Pretibial edema.

She was resuscitated and investigated with a multidisciplinary team. Laboratory examinations demonstrated hemoglobin 4.70g/dL; hematocrit 14.5%; white blood count 11.400cells/mL, platelets 51,000 cells/mL. Serum BUN, creatinine, SGOT, SGPT and ALP were normal, serum β - human chorionic gonadotropin (bhCG) >1500mU/ml (Fig. 5) and Urine dipstick revealed ++ proteinuria.

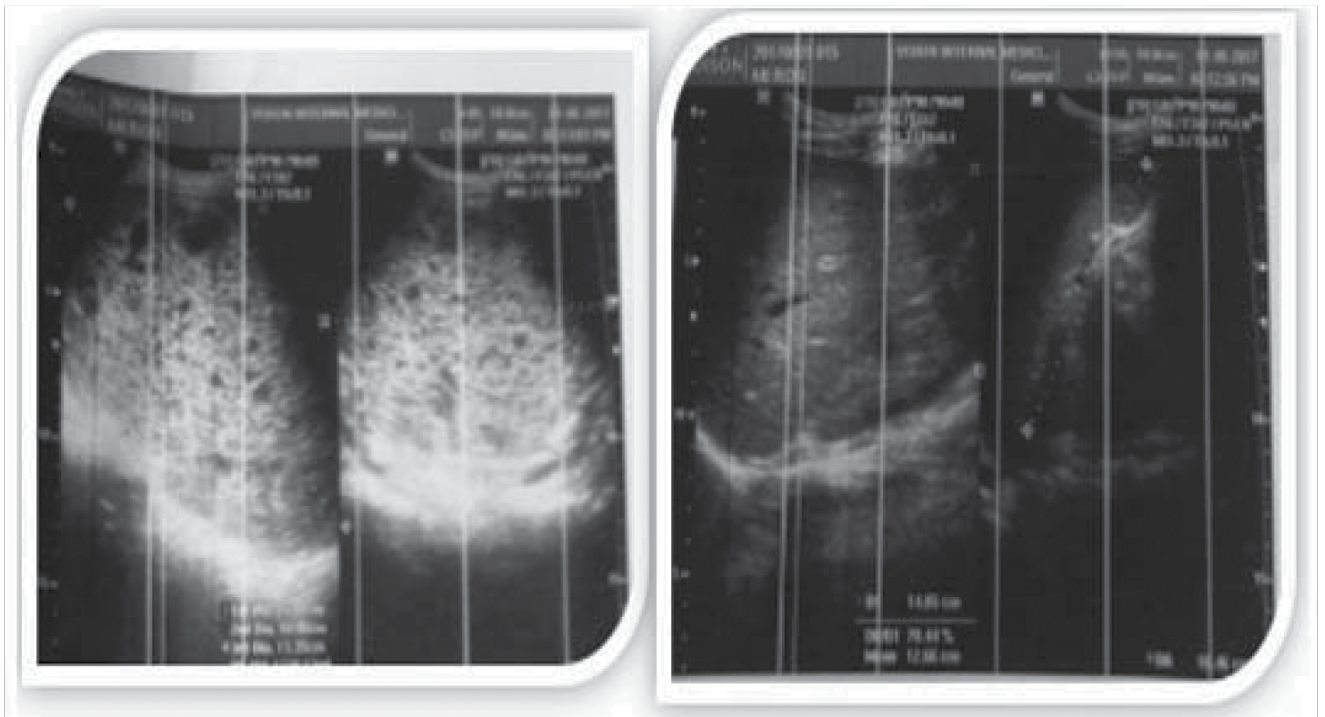


Figure 1: Trans abdominal ultrasound showed a molar pregnancy with minimal pleural effusion ECHO revealed a normal study.

Trans abdominal Ultrasound Hydatidiform Mole

With the diagnosis of severe preeclampsia, GI onset sepsis, severe anemia, hyperthyroidism, NYHA class III CHF and a probable complete molar pregnancy, the patient received MgSo₄ for seizure prophylaxis, antibiotics and Packed RBCs and was admitted to the ward planning management options including evacuation of the uterine content after stabilization of

the patient and securing blood and blood products. About 12 hours after the admission to the ward, she spontaneously expelled about 1500cc of grape like tissues and vesicles mixed with blood (fig 2). Suction & curettage was done to evacuate the uterus under general anesthesia. Evacuation of the Uterus was associated with rapid resolution of symptoms, and normalization of blood pressure and laboratory abnormalities.

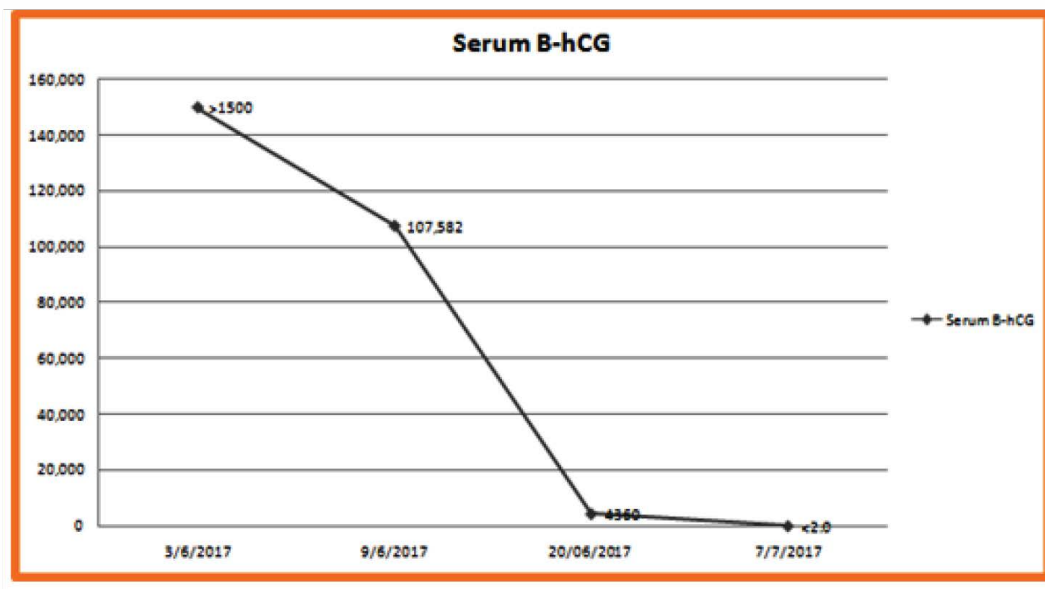


Fig-5: Trends of Serum B-HCG

The histopathology of the specimen showed it to be of incomplete molar pregnancy with no evidence of malignancy (fig 3). After 09days of stay in the hospital she was discharged in stable condition.

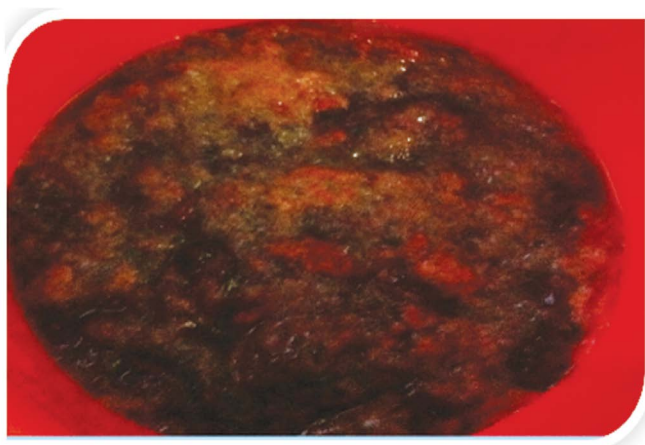


Fig. 2: The grapelike vesicles mixed with blood spontaneously expelled

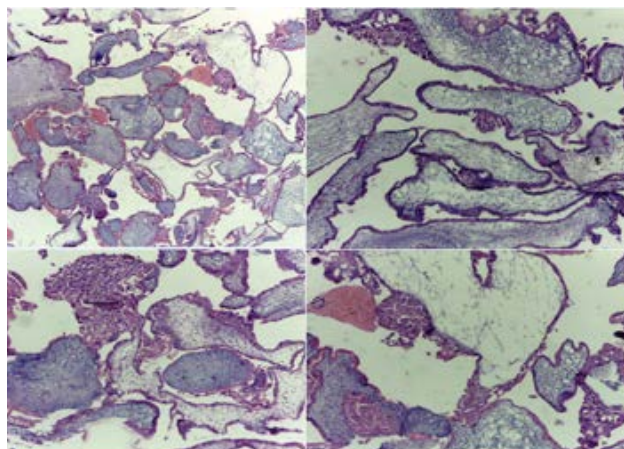


Fig. 3: The microscopic features of partial hydatidiform mole

Final Diagnosis was partial mole complicated by severe preeclampsia, partial HELLP and hyperthyroidism.

DISCUSSION

Gestational trophoblastic diseases (GTD)^{1,2,3,4} are a heterogeneous group of gestational and neoplastic conditions arising from the trophoblast. They include molar gestations and trophoblastic tumors (fig.4). GTD varies widely among various populations with occurrences as high as 1/120 pregnancies in some areas of Asia and South America, compared to 0.6–1.1 per 1000 in the United States⁵. The incidence in Addis Ababa, Ethiopia is 2.8/1000 pregnancies⁶. The incidence of hydatidiform moles is greater in women older than 40 years and younger than 20 years⁷.

Hydatidiform moles arise from abnormal conceptions. Molar pregnancies can be subdivided into complete (CM) and partial moles (PM) based on genetic and histopathological features. In a partial mole, there is usually evidence of a fetus or fetal red blood cells⁸. Most hydatidiform moles regress after suction evacuation, and the serum and urine HCG levels rapidly return to normal. Approximately 5–15% of patients with a hydatidiform mole progress to gestational trophoblastic neoplasia (GTN)⁹.

The Clinical manifestations of GTD include, in decreasing order of frequency: Vaginal bleeding, Enlarged uterus, Pelvic pressure or pain, Theca lutein cysts, Anemia, Hyperemesis gravidarum, Hyperthyroidism, Preeclampsia before 20 weeks of gestation & Vaginal passage of hydropic vesicles. Very rarely, women can present with acute respiratory failure or neurological symptoms such as seizures; these are likely to be due to metastatic disease⁸. Sometimes symptoms of hyperthyroidism are seen, due to extremely high levels of hCG which can mimic the thyroid stimulating hormone [TSH]. Conflicting evidence exists with respect to whether hCG is the thyrotropic factor responsible for stimulating thyrotoxicosis^{10,11}.

Pulmonary insufficiency is associated with about 2% of cases of complete hydatidiform mole^{12,13}. In these case,

acute respiratory distress occurs after molar evacuation and is almost invariably associated with marked uterine enlargement, or trophoblastic embolization, and also due to pulmonary hemorrhage¹⁴. Extensive pulmonary disease leads in some cases to cardiac enlargement and prominent pulmonary conus as a result due to acute cor-pulmonale. Other conditions include high output cardiac failure secondary to anemia and hyperthyroidism, eclampsia or fluid overload¹².

Patients with partial hydatidiform mole usually do not have the dramatic clinical features characteristic of complete molar pregnancy. In general, these patients have the signs and symptoms of incomplete or missed abortion, and partial mole can be diagnosed after histologic review of the tissue obtained by curettage. Fever or evidence of a bleeding diathesis should be investigated which is present because of uterine infection and disseminated intravascular coagulation are variably associated with molar pregnancy.

Ultrasound examination is helpful in making a pre-evacuation diagnosis but the definitive diagnosis is made by histological examination of the products of conception. The mole grossly represents a bunch of grapes [cluster of grapes, honeycomb uterus or snow storm appearance²². [fig.2]. In one study, the accuracy of pre-evacuation diagnosis of molar pregnancy increased with increasing gestational age, 35–40 % before 14 weeks increasing to 60% after 14 weeks¹⁵. A further study suggested a 56% detection rate for ultrasound examination¹⁶. The ultrasound diagnosis of a partial molar pregnancy is more complex; the finding of multiple soft markers, including both cystic spaces in the placenta and a ratio of transverse to anteroposterior dimension of the gestation sac of greater than 1.5, is required for the reliable diagnosis of a partial molar pregnancy^{17,18}. Estimation of β levels may be of value in diagnosing molar pregnancies: β levels greater than two multiples of the median may help¹⁶.

Severe preeclampsia is extremely uncommon prior to 24 weeks gestation¹⁵⁻¹⁹. The occurrence of HELLP syndrome prior to 20 weeks gestation has been reported only twice previously^{19,20}. In the case reported by Stefos

et al,¹⁵, diagnosis of a partial hydatidiform mole was suspected at 13.5 weeks gestation due to the sonographic appearance of the placenta and the maternal serum β - level of 200,000 mU/mL. At 18 weeks gestation, severe HELLP syndrome was diagnosed, with abnormal liver enzymes and platelet count < 50,000cells/mL. In the other case reported by Sherer et al²¹ the diagnosis is made with the ultrasound findings at 17 weeks gestation, and within 24 hours of the patient's initial symptomatology, her condition worsened significantly, with the development of severe HELLP syndrome with overt hemolysis and severe thrombocytopenia with a platelet count of 20,000cells/ml.

The case we present is unusual in that concurrent with the ultrasound findings at the 3rd month of amenorrhea, and within seven days of the patient's initial symptoms her condition worsened significantly, with the development of severe Preeclampsia with HELLP syndrome with high blood pressure and thrombocytopenia with severe anemia, sepsis and hyperthyroidism. This third report of HELLP syndrome occurring in conjunction with a partial mole at less than 20 weeks gestation associated with the above complications emphasizes that clinicians should be aware of the established as well as the unusual diagnostic characteristics of a partial mole. In addition, this case demonstrates the acuteness in which life-threatening maternal conditions may arise with this uncommon complication of pregnancy.

Suction curettage is the method of choice of evacuation for partial molar pregnancies except when the size of the fetal parts deters the use of suction curettage and then medical evacuation can be used⁸.

CONCLUSION

Early and proper diagnosis and management of the molar pregnancy and its complications is of utmost importance despite the unusual type of molar pregnancy. Ventilator support, cardiac failure correction and treatment of septicemia are the supportive treatment required until recovery in few cases²³. Strict follow up and contraception is advised to prevent confusion between normal pregnancy and recurrent molar pregnancy. In summary GTD may present in diverse and rare but life-threatening condition at unexpected time in the life span of a pregnancy.

CORRESPONDING AUTHOR:

Namus Muhajir Nur, MD

Department of Obstetrics and Gynecology, College of Health Sciences, Addis Ababa University, Addis Ababa, Ethiopia

REFERENCES

1. Management Guideline on Selected Topics in Obstetrics and Gynecology, Department of obstetrics and gynecology Faculty of medicine Addis Ababa University. Feb, 2004
2. F. Gary Cunningham, et al: Williams obstetrics, Mc Graw Hill Pub comp.; 24edition,2014
3. Jonathan S, Berek, Berek's& Novak's Gynecology,Lippincott Williams & Wilkins, a Wolters Kluwer business,15th ed,2012.
4. Pratap Kumar,Jeffcoat's principles of Gynecology, Jaypee Brothers medical publishers, 8th ed,2008
5. K. Hayashi, M. B. Bracken, D. H. Freeman Jr., and K. Hellenbrand, "Hydatidiform mole in the United States (1970-1977): a statistical and theoretical analysis,"American Journal of Epidemiology, vol. 115, no. 1, pp. 67-77, 1982.
6. Dereje N. et.al, Profile of HTD in two teaching hospitals, Addis Ababa, Ethiopia, Ethiopian J. Health Sci, Vol 17 No 4, march 2008
7. K. D. Bagshawe, J. Dent, and J. Webb, "Hydatidiform mole in England and Wales 1973-83," The Lancet, vol. 2, no. 8508, pp. 673-677, 1986.
8. The management of Gestational Trophoblastic Disease, RCOG Green Top Guideline, No.38, Feb 2010
9. J. R. Lurain, J. I. Brewer, E. E. Torok, and B. Halpern, "Natural history of hydatidiform mole after primary evacuation," American Journal of Obstetrics and Gynecology, vol. 145, no. 5, pp. 591- 595, 1983.
10. Curry SL, Hammond GB, Trey L, et al. Hydatidiform molar: diagnosis, management, and long term follow up of patients. *ObstetGynaecol.* 45; 1-8.
11. Amir SM, Osathonond R, Berkowitz RS, et al. Human chorionic gonadotrophin and thyroid function in patients with hydatidiform mole. *American journal of Obstet and Gynaecol.* 1994; 150:723-8.
12. Nisula BC and Taliadouros GS. Functions in gestational trophoblastic neoplasia; Evidence that the thyroid activity of human chorionic gonadotrophin mediates thyrotoxicosis of choriocarcinoma. *Journal of Obstet Gynaecol.*1980; 138:77-85.
13. Twiggs LB, Morrow CP, Schlaerth JB. Acute pulmonary complications of molar pregnancy. *American J ObstetGynaecol.* 138:77-85.
14. Kohorn EI. Clinical management and the neoplastic sequel of trophoblastic embolisation associated with hydatiform mole. 1978, *ObstetGynecolSurv.* 1987 Aug;42(8):484-8
15. Fowler DJ, Lindsay I, Seckl MJ, Sebire NJ. Routine pre-evacuation ultrasound diagnosis of hydatidiform mole: experience of more than 1000 cases from a regional referral center. *UltrasoundObstetGynecol* 2006; 27:56-60.
16. Johns J, Greenwold N, Buckley S, Jauniaux E. A prospective study of ultrasound screening for molar pregnancies in missed miscarriages. *Ultrasound ObstetGynaecol*2005; 25:493-7.
17. Fine C, Bundy AL, Berkowitz R, Boswell SB, Berezin AF, Doubilet PM. Sonographic diagnosis of partial hydatidiform mole. *ObstetGynecol* 1989; 73:414-18.
18. Benson CB, Genest DR, Bernstein MR, Soto-Wright V, Goldstein DP, Berkowitz RS. Sonographic appearance of first trimester complete hydatidiform moles. *J Ultrasound ObstetGynecol*2000; 16:188-91.
19. Stefanos T, Plachouras N, Mari G, Cosmi E, Lolis D. A case of partial mole and atypical type I triploidy associated with severe HELLP syndrome at 18 weeks' gestation. *Ultrasound ObstetGynecol* 2002; 20:403-404
20. Craig K, Pinette MG, Blackstone J, Chard R, Cartin A. Highly abnormal maternal inhibin and beta-human chorionic gonadotropin levels along with severe HELLP (hemolysis, elevated liver enzymes, and low platelet count) syndrome at 17 weeks' gestation with triploidy. *Am J ObstetGynecol* 2000; 182:737-739
21. sherer.et.al. Acute Onset of Severe Hemolysis, Elevated Liver Enzymes, and Low Platelet Count Syndrome in a Patient with a Partial Hydatidiform Mole at 17 Weeks Gestation. *American Journal of perinatology*/Volume 23, number 3/ 2006
22. Dr. Purnima deb, et al.: Molar pregnancy with multiple organ dysfunction, an interesting case report. *Int. J. Med. Public health* [www.ijmedph.org] | January-March 2011 | Vol 1 | Issue 1
23. Hankins C, Wendel GD, Snyder RR, et al. Trophoblastic embolization during molar evacuation: Central haemodynamic observations. *Obstetrics and gynaecology.*1987; 7:247-51.
24. Szulman AE: Trophoblastic disease: Clinical pathology of hydatidiform moles. *ObstetGynecolClin North Am* 15: 433, 1988
25. Szulman AE, Surti U: The syndromes of hydatidiform moles: I. Cytogenetic and morphologic correlations. *Am J ObstetGynecol* 131: 665, 1978
26. Szulman AE, Surti U: The syndromes of hydatidiform moles: II. Morphologic evolution of the complete and partial mole. *Am J ObstetGynecol* 132: 20, 1978
27. Szulman AE, Surti U: The clinicopathologic profile of the partial hydatidiform mole. *ObstetGynecol* 59: 597, 1982