

## SPONTANEOUS HETEROTOPIC PREGNANCY: A CASE REPORT

Getachew Ahmed Endire, MD<sup>1</sup>, Endalkachew Mekonnen Assefa, M.D.<sup>2</sup>

### ABSTRACT

#### INTRODUCTION:

Heterotopic pregnancy refers to the presence of simultaneous pregnancies at two or more different implantation sites; commonly both intrauterine and extrauterine gestation. It is a rare and life-threatening condition which is difficult to diagnose and easily missed. We report an extremely rare case of heterotopic pregnancy after natural conception with cardiac activity noted on sonography in both the intrauterine and the ectopic pregnancy.

#### CASE PRESENTATION

A 38 years old gravida 2 para 1 mother diagnosed with heterotopic pregnancy despite lack of any notable risk factors at a gestational age of 11weeks and 6 days. Trans-vaginal ultrasound showed alive intrauterine pregnancy and right adnexal ectopic pregnancy with a heartbeat. She underwent exploratory laparotomy and right salpingectomy was done and discharged home with a stable clinical condition; and had uneventful antenatal visits. She delivered by emergency C- section at 39 weeks & 3 days gestation for an indication of non-reassuring fetal heart rate pattern.

#### CONCLUSION:

This un-common case demonstrates the possibility of occurrence of natural heterotopic pregnancy and clinical detection helped for a good maternal and fetal outcome.

Keywords: Ectopic pregnancy; Heterotopic pregnancy, Spontaneous

(The Ethiopian Journal of Reproductive Health; 2-20; 12;41: 60-64)

---

<sup>1</sup> Department of Obstetrics and Gynecology, College of Health Sciences, Addis Ababa University, Addis Ababa, Ethiopia

<sup>2</sup> Department of Obstetrics and Gynecology, College of Health Sciences, Addis Ababa University, Addis Ababa, Ethiopia

## INTRODUCTION

Heterotopic pregnancy was first reported in 1708 by Duverney as an incidental finding of intrauterine pregnancy while doing an autopsy of a patient who died due to ruptured ectopic pregnancy. Heterotopic pregnancy refers to the presence of simultaneous pregnancies at two or more different implantation sites and commonly the coexistence of intrauterine pregnancy (IUP) and extrauterine gestation<sup>1</sup>. The incidence in the general population is estimated to be about 1 in 30,000, while becoming commoner with assisted reproductive technique a rate as high as 1 in 2600-3900 pregnancies<sup>2</sup>. The fallopian tube is the site of the vast majority of the ectopic implantation in heterotopic pregnancies, but the cervix or abdomen can also be involved<sup>3</sup>.

Risk factors are any event that can lead to scarring of the fallopian tube can increase the risk of an ectopic pregnancy include pelvic inflammatory disease (PID), tubo-ovarian abscess (TOA), previous ectopic pregnancies, or previous surgery<sup>4</sup>. Heterotopic pregnancy is thought to occur because of multiple ovulation events<sup>5</sup>. Therefore, individuals who have undergone assisted reproduction therapies are at an increased risk of heterotopic pregnancy<sup>6</sup>.

Individuals often present with four common symptoms: abdominal mass, abdominal pain, peritoneal irritation, and enlarged uterus, although early symptoms can also be similar to those seen in acute appendicitis, ovarian cyst rupture, or ovarian torsion<sup>7</sup>.

It can be a life-threatening condition and can be easily missed with the diagnosis being overlooked. Diagnosis is challenging, as it is often difficult to identify both the IUP and extra uterine pregnancy. Ultrasound often leads to the suspected presence of the associated ectopic pregnancy, but is not confirmatory<sup>8,10</sup>. A common pitfall noted in previous reports is ceasing the workup after identification of an IUP in women with abdominal pain<sup>9</sup>. Approximately 70% of heterotopic pregnancies are diagnosed between 5 to 8 weeks, 20% are diagnosed between weeks 9 and 10, and the remaining 10% are diagnosed at or beyond the 11th week<sup>10</sup>. Due to the rarity of heterotopic pregnancy, there is little agreement regarding the optimal surgical management<sup>11</sup>. Treatment of heterotopic pregnancy should be as

minimally invasive as possible to preserve the developing IUP. Laparoscopy or laparotomy can be performed, with slight modifications such as avoiding excessive manipulation of the uterus<sup>12</sup>. Non-surgical forms of treatment are available such injection of potassium chloride to selectively reduce the extrauterine gestation has been used<sup>13</sup>. We present a rare case of spontaneous heterotopic pregnancy with live intrauterine gestation and ruptured right adnexal gestation.

## CASE PRESENTATION

A 38 years old gravida 2 para1 mother amenorrhoeic for the last three months presented to the emergency OPD with complaints of lower cramping abdominal pain which is more pronounced on the right side and intermittent vomiting of the ingested matter of four days duration and mild epigastric abdominal pain. Otherwise, she has no other complaints and notable risk factors.

Physical examination revealed stable vital signs (blood pressure 110/70 mmHg, pulse 100 bpm, temperature 36.1° C, respirations 18/minute, oxygen saturation 97% with atmosphere air); pink conjunctiva, mild rebound, and diffuse abdominal tenderness and guarding. There was no palpable mass or sign of fluid collection on abdominal palpation. Cervix was closed and there was no bulging of cul-de-sac, cervical motion tenderness and blood on examining finger.

Hematocrit was 34.9% and transvaginal ultrasound showed a simultaneous alive (positive cardiac activities) IUP with CRL=11 weeks+1day and right adnexal ectopic pregnancy with CRL=11 wks+3days (Fig 1).

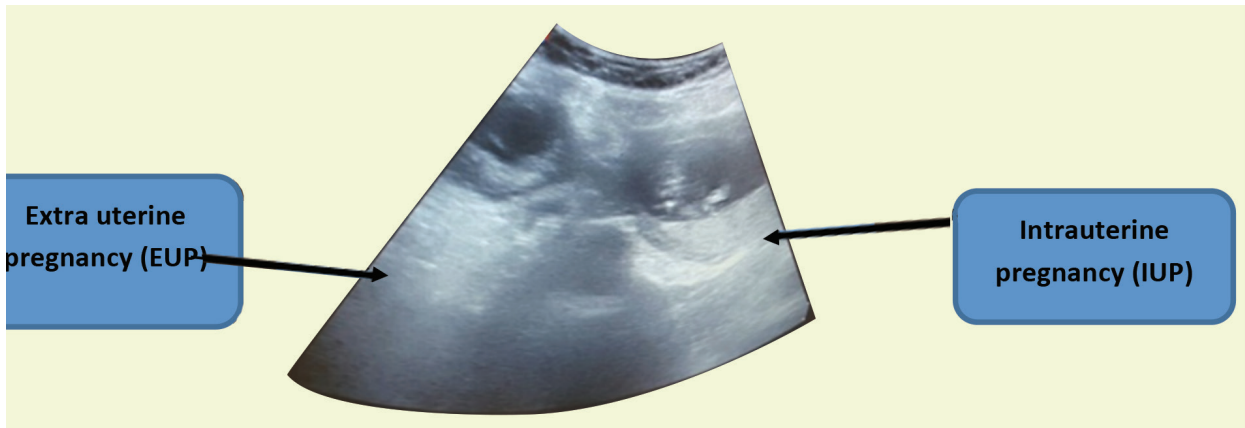
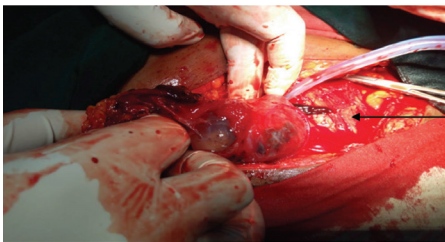


Figure 1- transvaginal ultrasound showing both intra and extra uterine pregnancy

Exploratory laparotomy was done after four hours of first evaluation and cross-matched blood prepared and consented for the above procedure and possible right salpingectomy. The intraoperative findings were a 6X6 cm right ampullary gestational sack with active bleeding through the fimbrial opening (fig. 2) and there was healthy looking left tube and both ovaries. There was 14 weeks size intact gravid uterus. About 500 ml of hemoperitoneum was sucked out. Right salpingectomy was done. Throughout the procedure, uterine manipulation was minimized.



a tubal ectopic pregnancy was seen in the right fallopian tube

Figure 2.ectopic pregnancy was seen in the right fallopian tube (arrowhead).

Her vital signs were stable throughout the hospital stay and her post-operative hemoglobin was 10.2g/dL. She was discharged with stable vital signs and intact intrauterine pregnancy, with cardiac activity. Histopathology confirmed ectopic pregnancy (fig 3). She had uneventful antenatal care and she gave birth at 39 weeks 3 days gestation via an emergency cesarean section

for non-reassuring fetal heart rate. The male newborn was alive weighing 3.2kg with APGAR score of 8 and 9 at first and fifth minute, respectively. The mother and her baby were discharged with stable conditions and had uneventful postnatal visits.

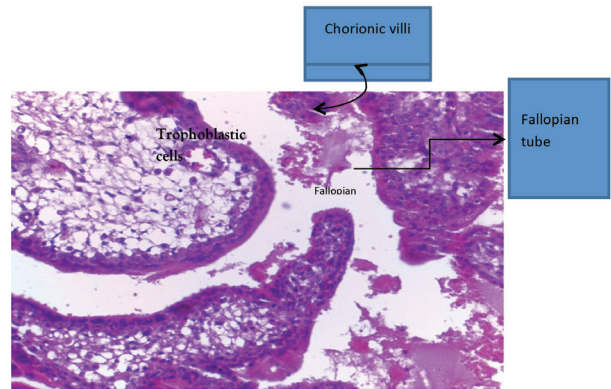


Figure 3.Histopathology picture showing chorionic villi with trophoblastic cells in the wall of the fallopian tube

## DISCUSSION

This case represents a spontaneous heterotopic pregnancy in a 38-year-old patient with no obvious previous risk factors identified. Making an early diagnosis of heterotopic pregnancy may not be easy in our context where first trimester and emergency room pelvic ultrasonography are not routinely performed.

Pelvic ultrasonography confirms the diagnosis when an extrauterine gestational sac is seen. It has been shown that transvaginal pelvic ultrasonography makes a correct diagnosis in 88.9% of cases<sup>14</sup>.

The treatment options of heterotopic pregnancy can be surgical, medical or expectant depending on the case scenarios. Out of 217 cases of heterotopic pregnancies reported in the literature, 90.8% were managed surgically<sup>15</sup>. The procedure usually consists of salpingectomy via laparotomy or laparoscopy depending on the patient's hemodynamic state at the time of diagnosis. Heterotopic pregnancy can be managed medically under the following conditions: early and accurate diagnosis of the extra-uterine gestational sac and absence of symptoms but our case didn't fulfill the criteria for medical management. Several modalities have been reported with success: ultrasound-guided vaginal aspiration or in situ injection of methotrexate, potassium chloride or hyperosmolar glucose<sup>16</sup>. Expectant management of the ectopic pregnancy can be considered if it is not developing. The maternal outcome is measured through the following parameters: post-operative morbidity, complications of surgery and anesthesia, anemia, future fertility, and death. All these can be avoided by early diagnosis and medical or expectant management<sup>15</sup>. Our patient did well and discharged on the sixth postoperative day. Three main measures were implemented to preserve the intra-uterine pregnancy: shortest time under general anesthesia, proper handling of the uterus during surgery and supplementation with progesterone. The progesterone was given to make the uterus quiescent or less irritable and to prevent threatened abortion. A Cochrane Review of seven trial involving 696 participants who is at risk of threaten abortion suggest that progestogens are probably effective in the prevention of threatened miscarriage<sup>17</sup>. A literature review found a survival rate of about 70% for the intra-uterine fetus<sup>14</sup>. In our case, the intrauterine fetus was born alive at term. Surgical management of tubal pregnancy allowed the viable IUP to develop to term on our case.

#### **CORRESPONDING AUTHOR:**

Getachew Ahmed, MD

Department of Obstetrics and Gynecology, College Health Sciences, Addis Ababa University, Addis Ababa, Ethiopia

Email: gech200094@yahoo.com

## REFERENCES

1. Reece EA, Petrie RH, Sirmans MF, Finster M, Todd WD (1983) Combined intrauterine and extrauterine gestations: a review. *Am J ObstetGynecol* 146: 323-330?
2. Tal J, Haddad S, Gordon N, Timor-Tritsch I. Heterotopic pregnancy after ovulation induction and assisted reproductive technologies: a literature review from 1971 to 1993. *FertilSteril* 1996; 66:1.
3. Hassani KI, Bouazzaoui AE, Khatouf M, Mazaz K (2010) Heterotopic pregnancy: A diagnosis we should suspect more often. *J Emerg Trauma Shock* 3: 304.
4. Tal J, Haddad S, Gordon N, Timor-Tritsch I (1996) Heterotopic pregnancy after ovulation induction and assisted reproductive technologies: a literature review from 1971 to 1993. *FertilSteril* 66: 1-12.
5. Wang PH, Chao HT, Tseng JY, Yang TS, Chang SP, et al. (1998) Laparoscopic surgery for heterotopic pregnancies: a case report and a brief review. *Obstetrics & Gynecology and Reproductive Biology* 80: 267-271.
6. Berger MJ, Taymor ML (1972) Simultaneous intrauterine and tubal pregnancies following ovulation induction. *American Journal of Obstetrics & Gynecology* 113: 812-813.
7. van Dam PA, Vanderheyden JS, Uyttenbroeck F (1988) Application of ultrasound in the diagnosis of heterotopic pregnancy—a review of the literature. *J Clin Ultrasound* 16: 159-165.
8. Kwon YS, Lee SH, Im KS, Ro JH (2015) Laparoscopic Management of Heterotopic Interstitial Pregnancy with Subsequent Term Delivery. *Int J FertilSteril* 9: 265-267.
9. Louis-Sylvestre C, Morice P, Chapron C, Dubuisson JB (1997) The role of laparoscopy in the diagnosis and management of heterotopic pregnancies. *Hum Reprod* 12: 1100-1102.
10. Bassil S, Pouly JL, Canis M, Janny L, Vye P, et al. (1991) Advanced heterotopic pregnancy after in-vitro fertilization and embryo transfer, with survival of both the babies and the mother. *Hum Reprod* 6: 1008-1010.
11. F. Jan, G. M. Naikoo, M. H. Rather, T. A. Sheikh, and Y.H. Rather, "Ruptured heterotopic pregnancy: a rare cause for hemoperitoneum; report of three cases from Kashmir, India," *Indian Journal of Surgery*, vol.72, no.5, pp.404-406,2010
12. Reece EA, Petrie RH, Sirmans MF, Finster M, Todd WD.
13. Diallo D, Aubard Y, Piver P, Baudet JH. Grossessehétérotopique: à propos de cinq cas et revue de la littérature. *J GynecolObstetBiol Reproduction*. 2000; 29(2):131-Combined intrauterine and extrauterine gestation: a review. *Am J of ObstetGynecol* 1983; 146(3):323-30. Google Scholar
14. Allison JL, Aubuchon M, Leasure JD, Schust DJ. Hyperosmolar glucose injection for the treatment of heterotopic ovarian pregnancy. *Obstet Gynecol*. 2012; 120(2):449-
15. V.Mihmanli,A.Kilickaya,N.Cetinkaya,G.Karahisar,and H. Uctas, "Spontaneous heterotopic pregnancy presenting with hemoperitoneum," *he Journal of Emergency Medicine*,vol.50,no. 1, pp. 44-46, 2016.
16. A. J. Headley and V. Adum, "Naturally occurring heterotopic pregnancy in a multiparous patient: a case report," *Journal of Reproductive Medicine*,vol.58,no.11-12,pp.541-544,2013.
17. Wahabi HA, Fayed AA, Esmail SA, Bahkali KH. Progesterone for treating threatened miscarriage. *Cochrane Database of Systematic Reviews* 2018, Issue 8. Art. No.: CD005943