

CERVICAL ECTOPIC PREGNANCY AFTER IVF: A CASE REPORT OF SUCCESSFUL CONSERVATIVE MANAGEMENT WITH TRANSVAGINAL AMNIOTIC SAC ASPIRATION AND INTRA SACCULAR METHOTREXATE INJECTION

Feruz Surur, MD¹, Mutesim Abdulahi MD²,

ABSTRACT

Cervical Ectopic Pregnancy (CEP) is a very rare condition accounting for less than 1 % of all Ectopic Pregnancies. Early diagnosis and management of the case is very essential in order to avoid serious and life threatening complications which are difficult to successfully manage in resource poor settings. Here we are presenting a case report of a 38 yr. old Ethiopian mother who developed CEP following her 1st IVF therapy for a secondary infertility secondary to Asherman's syndrome. She was successfully managed conservatively, with aspiration and subsequent instillation of methotrexate in to the gestational sac. Early diagnosing with transvaginal ultrasound and serial B HCG measurement coupled with immediate therapeutic measures are the key issues in preventing the severe life threatening complications of CEP and conserve the subsequent fertility potential of such patients.

(The Ethiopian Journal of Reproductive Health; 2022; 15;47-53)

1 St. Paul's Hospital, Millennium Medical College, Addis Ababa, Ethiopia

2 Jijjiga University, Jigjiga, Ethiopia

INTRODUCTION

Cervical Ectopic pregnancy (CEP) is a rare life-threatening condition and represents less than one percent of all ectopic pregnancies. The etiology of CEP is not fully understood but reported risk factors for CEP include history of pelvic inflammatory disease, smoking, previous pelvic surgery, previous ectopic pregnancy, intrauterine device use, anatomic anomalies, previous cesarean delivery, previous uterine or cervical surgery, in vitro fertilization, and diethylstilbestrol exposure ^{1, 2, 3}.

Five clinical signs of cervical ectopic pregnancy were identified in an article by Paalman: uterine bleeding without cramping pain after a period of amenorrhea, softened and disproportionately enlarged cervix equal to or larger than the corporal portion of the uterus (an hourglass-shaped uterus), products of conception entirely confined within, and firmly attached to, the endo cervix, a snug internal os, and, a partially opened external os ⁴.

The most feared complication in CEP is the life-threatening vaginal bleeding associated with the high risk of emergency hysterectomy and massive blood transfusions. In the past, hysterectomy was often the only choice available due to extensive and uncontrollable hemorrhage ⁵.

Advances in ultrasonography technology and the availability of quantitative beta-human chorionic gonadotropin (β -hCG) have made diagnosis of CEP possible at an early gestational age when the woman is still asymptomatic. Early diagnosis of CEP which is essential to allow for careful planning of more conservative procedures in those patients who desire future childbearing ⁶. Diagnosis of CEP could be made on sonography if the following criteria are fulfilled: 1) an empty uterus, 2) a barrel-shaped cervix, 3) a gestational sac present below the level of uterine arteries, 4) absence of the sliding sign (when pressure is applied to the cervix using the probe, the gestational sac slides against the endo cervical canal in a miscarriage, but does not in an implanted cervical pregnancy) and 5) blood flow around the gestational sac on color Doppler ⁷.

The differential diagnosis of CEP is a prior intrauterine gestational sac in the process of being expelled from the uterine cavity. The main difference between these clinical situations is that in CEP the internal os of the cervical canal is closed, whereas in cervical abortion it is dilated.

So far, there is no an established single “gold standard” treatment of choice; in the management of more advanced CEP. Conservative approaches are increasingly preferred by many.

Here, the authors describe a case of a hemodynamically stable nulliparous woman diagnosed to have a 7weeks CEP and managed successfully with aspiration of amniotic sac and intra saccular installation of MTX. The diagnostic approach along with therapeutic options available for the management of CEP in hemodynamically stable patients are discussed.

CASE REPORT

Our patient is a 38yrs old G2P0A1 mother who presented with a chief c/o mild intermittent crampy abdominal pain of 2 days duration. Four weeks prior to her presentation she had had an IVF procedure with a single fresh transfer of a day 3 embryo. She gave history of in ability to conceive of 6yrs duration following her first pregnancy which ended up in 1st trimester spontaneous abortion, which was treated with MVA. Subsequently, she reported that her menses has been drastically reduced. After a diagnosis of Uterine Synechiae, A hysteroscopic excision of an intrauterine adhesive septum and scar was made. IUCD was left in situ for 2 months. She was then enrolled in to IVF scheme. The current pregnancy was achieved after an uneventful ovarian stimulation with a mild protocol and a fresh, single, day three embryo transfer. An assay of serum beta hcg was used to confirm the pregnancy on 14th day of embryo transfer and the titer was 355 IU that doubled to 698 IU after the subsequent 48hrs. Corpus luteal support continued and She was then scheduled for ultrasound evaluation after 2 weeks. She came 15 days after the positive test for her scheduled ultrasound, but also complains of mild

lower abdominal and lower back discomfort. Otherwise, she was not showing any sign of pain or distress.

Her vital signs were normal. There were no any abnormal findings on general physical examination. Trans vaginal ultrasonography showed empty

endometrial cavity and a gestational sac of 2 x3 cm in the posterior wall of the cervix below the internal os and with a yolk sac and fetal pole but no visible FH activity (Fig 1). Sliding sign was negative. There was adequate blood flow around the sac.

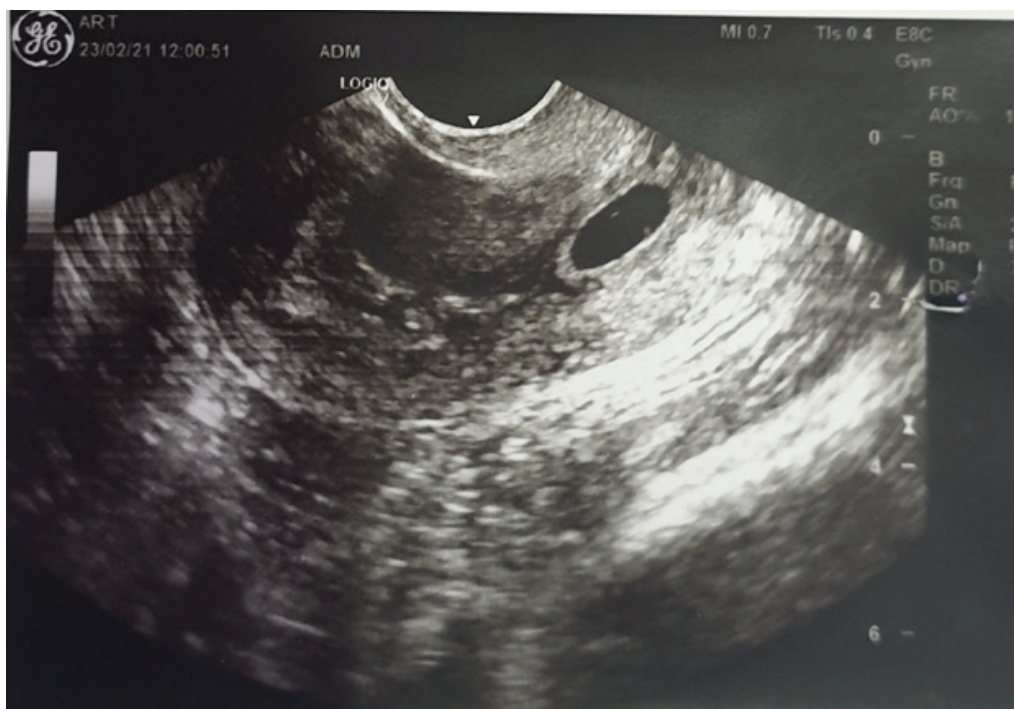

Figure 1. A transvaginal image a cervical pregnancy. Note a gestational sac on the posterior wall of the cervix below the level of the internal os.

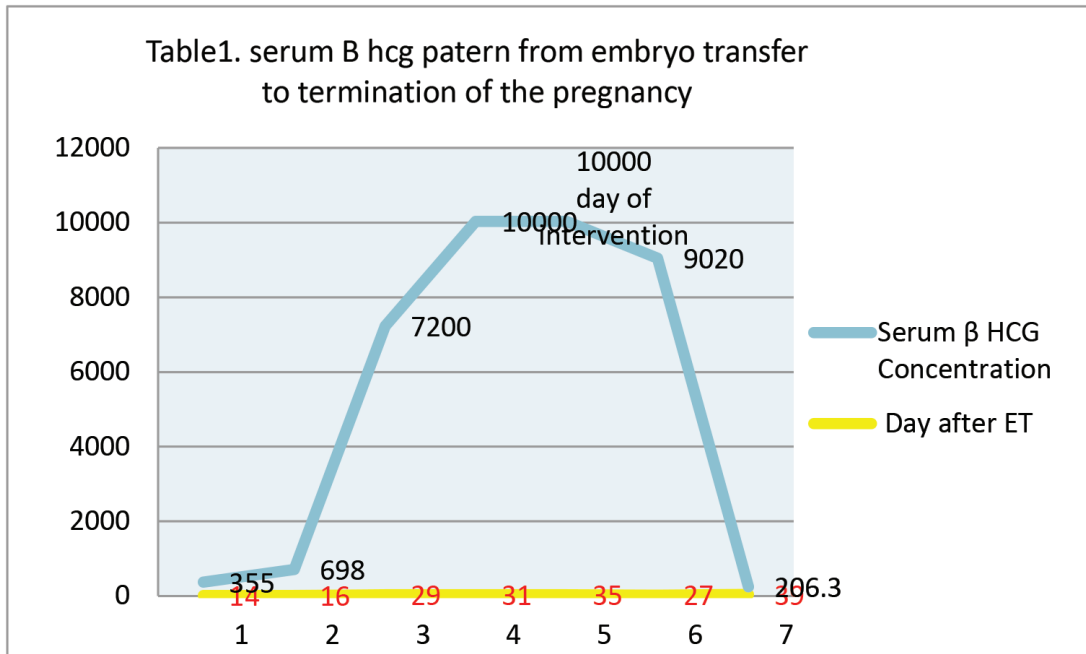
Speculum examination revealed a healthy, but slightly enlarged cervix. Bimanual examination was avoided for fear of rupture.

Lab investigations were all normal: hemoglobin was 12.6gm, blood group B positive. Serum B HCG on this day was 7200 IU.

With these findings, a diagnosis of CEP was made, patient was counseled about the potential dangers and prognosis and admitted to the ward. The next day, TVS was repeated and a similar finding was observed. Following a written consent, she was taken to the operation theatre where under general but light anesthesia and using a transvaginal ultrasound guidance the gestational sac first was

aspirated and a 50mg of methotrexate was instilled through the same needle in situ. (Figure 2, TVS, immediately after aspiration). Since both intra and post-operative course of the patient were stable she was discharged after a 12 hrs. of stay with an advice on the need for close follow up, with clinical, ultrasound and Beta HCG monitoring.

Beta HCG 48 hours later was 9020 iu. TVS, revealed swollen cervix with no sac or fetal pole. Subsequently Beta HCG continued to drop when it came to less than 5, 3 weeks after the procedure. (Figure 2) shows the drop in beta HCG.



The cervical swelling also continued to subside. (Figure 3). She experienced dark menstruation like bleeding on the third week after the intervention which subsided by itself.

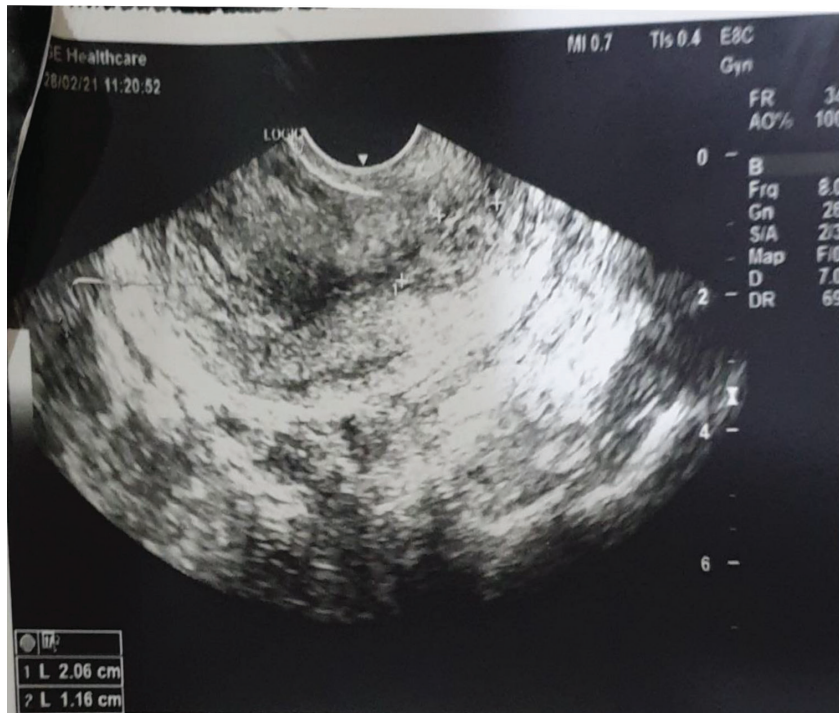

Figure 3, picture of TVS, 10 days after intervention showing shrinking cervical swelling

DISCUSSION

To our best knowledge and literature reviews, this is the first reported case of CEP in Ethiopia. Most of reported cases of CEP elsewhere dwell on the potential complication and surgical management of CEP, including hysterectomy. With the advancement of TVS and introduction of medical management of ectopic pregnancy in general, early detection and conservative management are being increasingly reported globally⁸. Conservative therapy is important in CEP patients, for it is less invasive, less risky and better particularly for those who desire fertility preservation. A review of the literature shows, although mainly consisting of case reports, that the present treatment standard in asymptomatic CEP is MTX combined with intra-amniotic feticide in the case of a viable pregnancy⁹. Controversy remains about the criteria for a safe and successful medical or, on the other hand, surgical treatment. Many attempts are described to determine special risk factors predictive of the success rate of an either conservative or surgical procedure. The clinical conditions for the conservative medical approach were outlined by Ushakov et al.¹⁰.

For conservation of the uterus various therapeutic options are described including medical management with cytotoxic agents such as systemic MTX injection, either as a single dose or serial injections with leucovorin rescue, misoprostol, mifepristone, and interventional measures, for example the US-guided injection of MTX, potassium chloride (KCl) or vasopressin directly in the gestational sac intracervical carboprost injection and needle aspiration of the products, use of a Foley catheter to tamponade the endo cervix after dilatation and curettage and cervical cerclage¹¹⁻¹⁶. Other conservative options include the use of laparoscopic surgical ligation of blood vessels, hysteroscopic excision, and angiographic uterine artery embolization, stepwise de vascularization of the uterus, internal iliac artery ligation, angiographic UAE, intracervical carboprost injection and needle aspiration of the products⁹⁻¹⁴ with a high degree

of success and minimal morbidity^{3, 8, 14}.

Our patient who presented with multiple risk factors for developing CEP that includes history of previous abortion, Asherman's syndrome, hysteroscopic excision of an intrauterine adhesion and use of an IUCD was successfully managed with transvaginal amniotic aspiration and intra-saccular methotrexate injection thus underscoring the importance of early diagnosis and treatment of CEP before a dire life threatening obstetric events transpire. Early diagnosis and treatment are important to decrease associated morbidity and requirement for further interventions that may not even be available and affordable in our usual poor setups.^{17/18}.

The use of MTX has become one of the most widely used options in the management of cervical ectopic pregnancies^{12,13} and in our setup this is a relatively possible and easily affordable option. Combining, transvaginal amniotic aspiration as is done in selective feticide and intra-saccular administration of methotrexate is considered because it is expected to reduce the total requirement of systemic methotrexate thus conserve already dwindling ovarian reserve in our patient.

Our management of this case supports its use in the conservative treatment of cervical ectopic pregnancies. Patients should be hospitalized due to the possibility of potentially serious complications. If, after initial methotrexate administration, there is an inadequate decrease of hCG levels, a repeat dose of MTX administration or UAE with or without immediate curettage might be performed to boost the effects of MTX^{8, 15,19}. Our patient, showed progressive decline in BHCG and reduction in the size of cervical swelling.

In patients with heterotopic pregnancies direct or ultrasound guided KCl injections might be the conservative modality of choice⁷. Intra-cardiac KCl injection might make methotrexate treatment more effective in cases where fetal cardiac activity is present (8). Intensive post-treatment surveillance and monitoring serum hCG levels weekly appears essential in decreasing morbidity.

Overall, the need for primary surgical treatment in CEP increases with advancing gestational age¹⁷. In this clinical situation significant and life-threatening vaginal hemorrhage remains the major concern. Some points must be kept in mind whenever a safe clinical management option of advanced CEP is to be implemented: in asymptomatic patients presenting with CEP primary conservative medical management using MTX or KCl is always a possible treatment option. At any time when treating a patient with CEP, a considerable amount of packed red blood cells must be held in reserve. Furthermore, local or systemic measures ensuring hemostasis such as cervical tamponade or blockade using a Foley catheter, percutaneous embolization of pelvic vessels in good setups, or surgical ligation of cervical branches of uterine arteries must be available immediately. Also to be ensured is that urgent laparotomy must be possible at any time. Conservative treatment of cervical pregnancy might be successful with careful follow up and subsequent conservative interventions. Since there is no a clear cut consensus in the literature as to which modality of treatment to start with (medical vs surgical), so far, the promising conservative treatment modalities need to be further evaluated through randomized controlled trials, to accomplish a standard stepwise treatment approach for this high-risk emergency. In summary, there are no guidelines available for clinicians. Therefore, each case of CEP must be managed individually taking the presented management modalities carefully into account

REFERENCES

1. Yazici G., Aban M., Arslan M., Pata O., Oz U.: "Treatment of a cervical viable pregnancy with a single intraamniotic methotrexate injection: a case report". *Arch. Gynecol. Obstet.*, 2004, 270, 61.
2. Ushakov F.B., Elchalal U., Aceman P.J., Schenker J.G.: "Cervical pregnancy: past and future". *Obstet. Gynecol. Surv.*, 1997, 52, 45.
3. Matteo M., Nappi L., Rosenberg P., Greco P.: "Combined medical hysteroscopic conservative treatment of a viable cervical pregnancy: a case report". *J. Minim. Invasive Gynecol.*, 2006, 13, 345.
4. M. M. Hosni, R. P. Herath, and M. Rashid, "Diagnostic and therapeutic dilemmas of cervical ectopic pregnancy," *Obstetrical & Gynecological Survey*, vol. 69, no. 5, pp. 261-276, 2014.
5. Cunningham FG, Gant NF, Leveno KJ, Gilstrap LC III, Hauth JC, Wenstrom KD (2001) Ectopic pregnancy, chapter 24. In: *Williams obstetrics*, 21st edn. McGraw-Hill, New York, pp 884-910
6. Monteagudo A, Minior VK, Stephenson C, Monda S, TimorTritsch IE (2005) Non-surgical management of live ectopic pregnancy with ultrasound-guided local injection: a case series. *Ultrasound Obstet Gynecol* 25:282-288
7. Kirk E., Condous G., Haider Z., Syed A., Ojha K., Bourne T.: "The conservative management of cervical ectopic pregnancies". *Ultrasound Obstet. Gynecol.*, 2006, 27, 430.
8. Verma U, Goharkhay N (2009) Conservative management of cervical ectopic pregnancy. *Fertil Steril* 91:671-674 8. Jeng CJ, Ko ML, Shen J (2007) Transvaginal ultrasound-guided treatment of cervical pregnancy. *Obstet Gynecol* 109:1076-1082
9. C. Jaeger . N. Hauser . R. Gallinat . R. Kreienberg . G. Sauer . R. Terinde Cervical ectopic pregnancy: surgical or medical treatment? *Gynecol Surg* (2007) 4: 117-121 DOI 10.1007/s10397-006-0224
10. Ushakov FB, Elchalal U, Aceman PJ et al (1996) Cervical pregnancy: past and future. *Obstet Gynecol Surv* 52:45
11. Monteagudo A., Minior V.K., Stephenson C., Monda S., TimorTritsch I.E.: "Non-surgical management of live ectopic pregnancy with ultrasound-guided local injection: a case series". *Ultrasound Obstet Gynecol.*, 2005, 25, 282.
12. Segal S, Mercado R, Rivnay B (2010) Ectopic pregnancy early diagnosis markers. *Minerva Ginecol* 62:49-62
13. De La Vega GA, Avery C, NemiroV R, Marchiano D (2007) Treatment of early cervical pregnancy with cerclage, carboprost, curettage, and balloon tamponade. *Obstet Gynecol* 109:505-507
14. Oliver R, Malik M, Coker A, Morris J (2007) Management of extra-tubal and rare ectopic pregnancies: case series and review of current literature. *Arch Gynecol Obstet* 276:125-15.
16. Verma U, Maggiorotto F (2007) Conservative management of second-trimester cervical ectopic pregnancy with placenta percreta. *Fertil Steril* 697:e13-e16
17. Yitzhak M, Orvieto R, Nitke S, Neuman-Levin M, Ben-Rafael Z, Schoenfeld A (1999) Case report:cervical pregnancy a conservative stepwise approach. *Hum Reprod* 14:847-849
18. Chen D, Kligman I, Rosenwaks Z (2001) Heterotopic cervical pregnancy successfully treated with transvaginal ultrasound guided aspiration and cervical stay sutures. *Fertil Steril* 75:1030-1033.
19. Bing Xu, Wang YK, Zhang YH, Wang S, Yang L, Dai SZ (2007) Angiographic uterine artery embolization followed by immediate curettage: an eYcient treatment for controlling heavy bleeding and avoiding recurrent bleeding in cervical pregnancy. *J Obstet Gynecol Res* 33:190-194.