

RUPTURED NONCOMMUNICATING RUDIMENTARY HORN PREGNANCY: A CASE REPORT

Demisew Amenu¹ and Getaneh Dejen¹

ABSTRACT

Pregnancy in the rudimentary horn is rare and carries grave consequences for the mother. Here, we report a case of 26-year G3P2 with 17 weeks gestation who presented with lower abdominal pain. Ultrasound showed hemoperitoneum with suspicion of abdominal ectopic pregnancy. Intraoperatively the diagnosis of ruptured left rudimentary horn pregnancy made. Fetus and placenta was removed followed by excision of the horn with ipsilateral salpingectomy done

KEYWORDS: Ruptured rudimentary horn pregnancy, Unicornuate uterus, uterine anomalies

(The Ethiopian Journal of Reproductive Health; 2023; 15;59-63)

¹ Department of Obstetrics and Gynecology, Jimma University, Jimma, Ethiopia

INTRODUCTION

A unicornuate uterus with a rudimentary horn results from the incomplete development of one of the Müllerian ducts and an incomplete fusion with the contralateral side. About 85% of rudimentary uterine horns are non-communicating.^{1,2} Women with a unicornuate uterus have a significantly lower live birth rate, and higher rates of overall miscarriage, ectopic pregnancy, preterm delivery and cesarean delivery.³

Pregnancy in a rudimentary horn is a rare condition reported with an incidence of 1 in 100,000 to 140,000 pregnancies. Rudimentary horn pregnancies account for 26.9% of ectopic pregnancies in unicornuate uterus.^{3,4}

The incidence of rupture in rudimentary horn pregnancy is observed in 90% of cases, mostly in second trimester, which can lead to a life-threatening condition for the mother because of heavy intraperitoneal bleeding.⁵

We report a case of ruptured rudimentary horn pregnancy at 17 weeks of gestation which was diagnosed intraoperatively.

CASE REPORT

A 26-year-old gravida 3 para 2 (both alive) mother who was amenorrheic for the past 4 months, started ANC visits at the local health center. She presented to Jimma Medical Center after she was referred from the local primary hospital with

the diagnosis of anemia secondary to ruptured ectopic pregnancy. Her chief complaint was lower abdominal pain of one-day duration which was crampy and non-radiating type. She had associated easy fatigability, tinnitus and vertigo, and otherwise had no fever chills or rigor. She had no history of chronic pelvic pain, ectopic pregnancy, or previous miscarriage. She had no personal or familial history of hypertension or diabetes.

On physical examination, she was acutely sick looking. Her vital signs were stable with the exception of slight tachycardia (pulse rate, 106 bpm). Her conjunctiva were pale and chest was clear and resonant. S1 and S2 were well heard, no murmur or gallop was heard. There was a 10cm ×10 cm ballotable non-tender subumbilical abdominal mass which was mobile and there were signs of fluid collection. On pelvic examination cervix was closed, smooth with no blood on the examining finger and no adnexal mass.

On ultrasound exam an empty uterus was seen (figure 1). A fetus with cardiac activity and aBPD measurement corresponding to 17 weeks was noted (figure 2). There was a significant intraperitoneal free fluid collection. Otherwise the liver and both kidneys were grossly normal. With the impression of abdominal ectopic pregnancy and moderate anemia, laparotomy was planned.

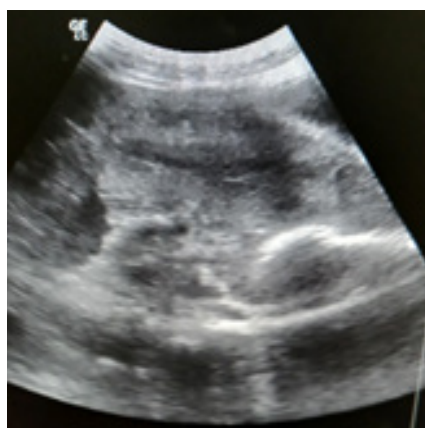


Figure 1 empty uterus

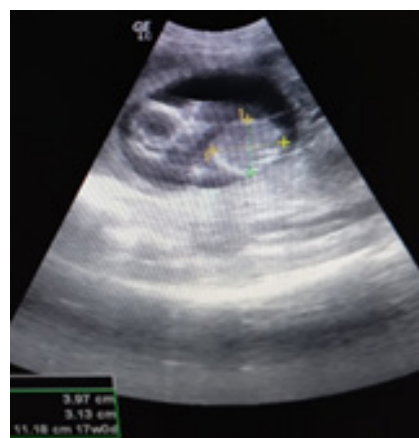

Figure 2 Alive fetus, BPD 17wks

Intraoperatively a right unicornuate uterus with a normal ovary and fallopian tube was found. To the left there was a rudimentary horn of uterus with fetus and placenta inside but ruptured on the posterior wall with active bleeding. The ipsilateral fallopian tube, ovary, and round ligament were normal. (Figure 3, 4)

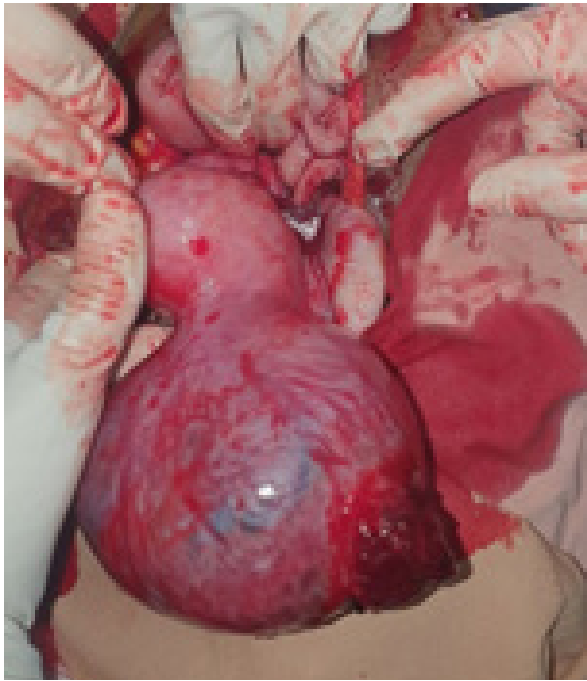

Figure 3 Unicornuate uterus with ruptured rudimentary horn pregnancy

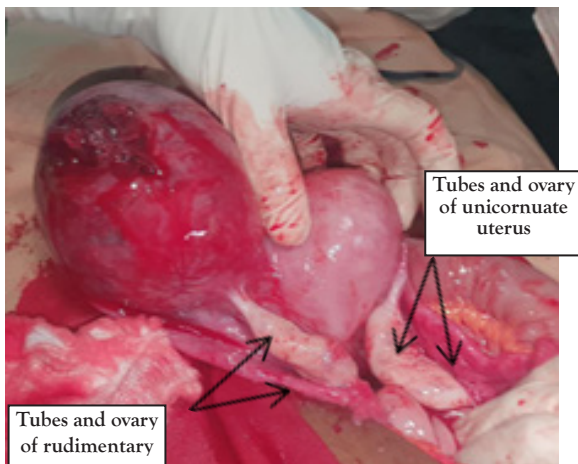


Figure 4 Normal tubes and ovaries of unicornuate uterus and rudimentary horn

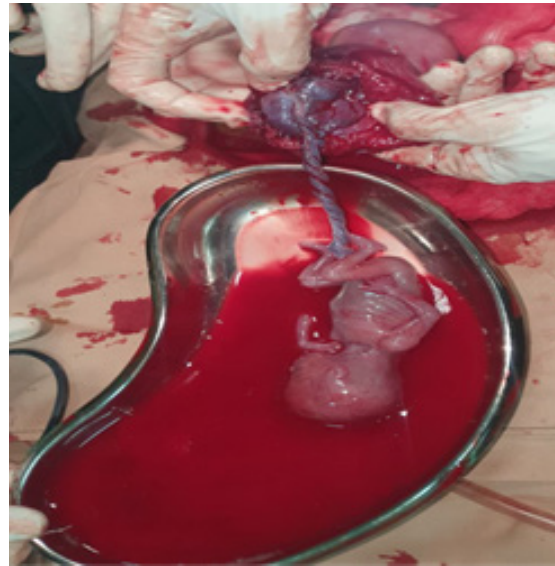

Figure 5 Fetus with placenta

The hemoperitoneum was evacuated and the fetus and the placenta were removed (figure 5). Ipsilateral round ligament was clamped, cut and ligated. Mesosalpinx serially clamped, cut and ligated. The ruptured rudimentary horn was clamped and resected at its base and hemostasis was secured. After the resection the sample was checked and showed no communication between the rudimentary horn and Unicornuate uterus. The abdominal cavity was cleaned and closed in layers. Intraoperatively, a diagnosis of ruptured non-communicating rudimentary horn of unicornuate uterus was made. She was transfused with three units of whole blood. The operative period was uneventful and she was discharged on her third postoperative day with ferrous sulfate tablets, advice and counseling.

DISCUSSION

According to the criteria from the American Fertility Society, unicornuate uteruses have 4 variants.⁶ Isolated unicornuate uteruses are the most common type, with a reported frequency of 35%. When a rudimentary horn is present, it is the noncavitary type in 33% of cases, the cavitary but noncommunicating type in 22% of cases which is typical of our case, and the cavitary and communicating type in 10% of cases.^{7,8} If

pregnancy occurs in cavitory rudimentary horn, the majority (80-90%) of cases occur in non-communicating type.

There is low preclinical and preoperative detection (14% overall) for rudimentary horn presentations.⁹ Therefore there should be a high index of suspicion. As in our case, the patient had two ANC visits to a rural health care center, and was followed there until rupture occurred and became symptomatic. She was referred later to our center as a case of ruptured ectopic pregnancy.

The early diagnosis of rudimentary horn pregnancy remains challenging even after the development of symptoms. In case series, reviewed by Li X et al. (2019) only one of 11 patients with rudimentary horn pregnancies (RHPs) was a known noncommunicating rudimentary horn. The other 10 patients received a false or misdiagnosis.⁹ Sometimes it was diagnosed after failed medical abortion.^{10,11} Even though ultrasound, hysterosalpingogram, hysteroscopy, laparoscopy, and MRI are the diagnostic tools¹², ultrasound is more accessible, especially in developing countries, but its sensitivity only 26% which depends on a variety of factors.¹³ Tubal pregnancy, cornual pregnancy, intrauterine pregnancy and abdominal pregnancy are common sonographic misdiagnosis.¹⁴ Even though the ultrasound was operator-dependent, it was mistaken in our case as an abdominal ectopic pregnancy because as gestational age rises, myometrium thins and reduces ultrasound's sensitivity.

If the condition is diagnosed antenatally, the main strategy is excision of the rudimentary horn either via laparotomy or laparoscopically¹⁵⁻¹⁷. In early gestation with unruptured RHP, medical management by methotrexate followed by laparoscopic excision is an option¹⁸, but in the majority of the cases diagnosed after rupture occur, immediate laparotomy is needed. In our case, we resected the rudimentary horn with its fallopian tube by laparotomy.

CONCLUSION

As preoperative and pre-rupture diagnosis rates are low, early diagnosis is the key to successful management. To lower morbidity and death, a high index of suspicion is therefore required. It should always be considered as a differential diagnosis in a pregnant woman presenting with lower abdominal pain especially in developing countries where the possibility of detection before pregnancy or before the rupture is less likely.

CORRESPONDING AUTHOR

Getaneh Dejen

Department of Obstetrics and Gynecology, Jimma University, Jimma, Ethiopia

E-mail: legetaneh@gmail.com

REFERENCES

1. Okonta PI, Abedi H, Ajuyah C, Omo-aghoja L. Case report Pregnancy in a noncommunicating rudimentary horn of a unicornuate uterus : a case report. *Cases J.* 2009;3:3-5.
2. Nahum GG. Feb02: Rudimentary Uterine Horn Pregnancy. *J Reprod Med.* 2002;47(2).
3. Tellum T, Bracco B, Braud LVDE, Knez J. Reproductive outcome in 326 women with unicornuate uterus. *Ultrasound Obs Gynecol* 2023; 2023;63:99-108.
4. Ambusaidi Q, Jha C. Pregnancy in the rudimentary uterine horn: Case report of an unusual presentation. *Sultan Qaboos Univ Med J.* 2014;14:134-8.
5. Venugopal G, Patil S, Manoli NS, Pratap T, Madhuri N. Case Report Ruptured rudimentary horn pregnancy : a case report. *Int J Reprod Contracept Obs Gynecol.* 2020;9(3):1271-3.
6. K Marten 1, R Vosshenrich, M Funke, S Obenauer, F Baum EG. MRI in the evaluation of mullerian duct anomalies. *Clin Imaging.* 2003;27(5):346-50.
7. Robert N. Troiano SMM. Müllerian Duct Anomalies: Imaging and Clinical Issues. *Radiol Case Reports.* 2004;33(1):19-34.
8. Khatri NJ, Frazier AA BK. The unicornuate uterus and its variants: clinical presentation, imaging findings, and associated complications. *J Ultrasound Med.* 2012;31(2):319-31.
9. Id XL, Peng P, Liu X, Chen W, Liu J, Yang J. The pregnancy outcomes of patients with rudimentary uterine horn : A 30-year experience. *PLoS One.* 2019;14(1):1-10.
10. Legesse AY, Teka H, Hassen A, Tinikishea EA. Pregnancy in the rudimentary uterine horn : a case report abstract. *Ethiop J Reprod Heal.* 2018;10(4):62-6.
11. Tesemma MG. Case Report Pregnancy in Noncommunicating Rudimentary Horn of Unicornuate Uterus : A Case Report and Review of the Literature. *Hindawi , Case Reports Obstet Gynecol.* 2019;
12. B. P. Lawhon, J. R. Wax and RTD. Rudimentary uterine horn pregnancy diagnosed with magnetic resonance imaging. *Obstet Gynecol.* 1998;91:869.
13. Jayasinghe Y, Rane A, Stalewski H GS. The presentation and early diagnosis of the rudimentary uterine horn. *Obs Gynecol.* 2005;105(6).
14. 8. Bahadori F, Borna S, Behroozlak T, Hoseini S AH. Failed induction in second trimester due to pregnancy in an uncommunicated rudimentary horn: case report. *J Fam Reprod Heal.* 2009;3(3):95-7.
15. PK H. Unicornuate uterus and rudimentary horn. *Fertil Steril.* 1997;68(2).
16. Arslan T, Bilgiç E, Sentürk MB YN. Rudimentary uterine horn pregnancy: a mystery diagnosis. *Fertil Steril.* 2009;92(6).
17. Tolu LB, Asrat M, Abortion S. Ruptured rudimentary horn pregnancy of unicornuate uterus ruptured rudimentary horn pregnancy of unicornuate uterus at hiwot fana specialized hospital , harar , ethiopia : a case report . *Ethiop J Reprod Heal.* 2019;11(2).
18. Sevtap HK, Aral AM SB. An early diagnosis and successful local medical treatment of a rudimentary uterine horn pregnancy: a case report. *Arch Gynecol Obs.* 2007;275(4):297-8.